

Metabolic heterogeneity of glycogen in hepatocytes of patients with liver cirrhosis: the glycogen of the liver lobule zones in cirrhosis

Margarita V. Kudryavtseva, Natalia N. Bezborodkina, Sergey V. Okovity and Boris N. Kudryavtsev

The concentrations of total glycogen (TG) and its labile (LF) and stable (SF) fractions were determined in hepatocytes of portal and central zones of the normal human liver and in the liver of patients with cirrhosis of viral and alcohol aetiologies. Using PAS reaction, TG, LF and SF were revealed in histological sections of the material obtained by the liver punch biopsies. The concentrations of TG and its fractions were measured by television cytophotometry. In liver cirrhosis, the concentrations of TG, LF and SF in both zones of the hepatic lobule have been found to be much higher than in the normal liver. It has been shown that the ratio of the hepatocyte TG concentrations in the portal zone to the central zone both in the normal liver and in viral cirrhosis exceeds 1.0, amounting to 1.264 ± 0.021 and 1.030 ± 0.009 , respectively. The glycogen fraction composition in the cells of both the liver lobule zones in

viral cirrhosis does not differ significantly from the norm. On the contrary, in the liver of patients with alcoholic cirrhosis, the ratio of the TG concentrations in the portal zone to the central zone is reduced to 0.815 ± 0.016 and is accompanied by qualitative changes of the glycogen composition. *Eur J Gastroenterol Hepatol* 13:693–697 © 2001 Lippincott Williams & Wilkins

European Journal of Gastroenterology & Hepatology 2001, 13:693–697

Keywords: cirrhosis, glycogen, liver, lobule, metabolic heterogeneity

Institute of Cytology, Russian Academy of Sciences, St Petersburg, Russia

Correspondence to Dr Margarita Kudryavtseva, Institute of Cytology, Russian Academy of Sciences, Tikhoretsky 4, St Petersburg 194064, Russia
Tel: +7 812 247 37 96; fax: +7 812 247 03 41;
e-mail: cellpath@link.cytspb.rssi.ru

Received 16 June 2000 **Revised** 2 October 2000

Accepted 25 October 2000

Introduction

The liver is the centre of human metabolism and performs many specialized functions. These functions are known to be carried out mainly by the liver parenchyma cells, hepatocytes. An essential factor affecting the hepatocytic activities is the metabolic heterogeneity of these cells due to the lobular structure of the liver. The zonal distribution of enzyme activities and concentrations of various substances in hepatocytes are connected closely with peculiarities of the liver blood supply and reflect the functional activity level of different zones of the liver lobule [1–4].

One of the main tissue-specific liver functions is maintenance of glucose homeostasis in the body, due to the ability of hepatocytes to utilize glucose, to store it in the form of glycogen, to synthesize it via gluconeogenesis, and to degrade glycogen in compliance with the body's requirements.

Chronic lesions of the liver inevitably affect its gluco-static function. Specifically, in many patients with chronic hepatitis and liver cirrhosis, the rapid normalization of the blood glucose level has been revealed to be impaired [5]. In these diseases, severe damage is observed in synthesis and degradation of liver glycogen.

Thus, the amount of glycogen in these hepatocytes increases, while the activity of glycogenolysis enzymes decreases [6–10].

Data on the state of carbohydrate metabolism in different zones of the liver lobule in chronic liver diseases are scarce. It has been reported that in human chronic hepatitis, the amount of glycogen in hepatocytes rises with changes of the ratio of its level in the cells of different liver lobule zones. These ratio changes in the portal and central lobule zones in patients with chronic hepatitis have been shown to characteristically depend on the aetiology of the liver pathology [11–13].

It is known that in liver cirrhosis not only do essential morphological and functional changes occur in hepatocytes, but also the lobular organization of the liver parenchyma is lost. Nevertheless, even in the cirrhotically altered liver there are occasional areas of parenchyma that preserve a relatively normal lobular structure. This allows us to evaluate the functional activity of cells in different zones of the liver lobule [11,13,14].

The goal of the current work was to study the distribution of total glycogen (TG) and its fractions in hepato-

cytes of the portal and central liver lobules in patients with liver cirrhosis of viral and alcoholic aetiologies.

Materials and methods

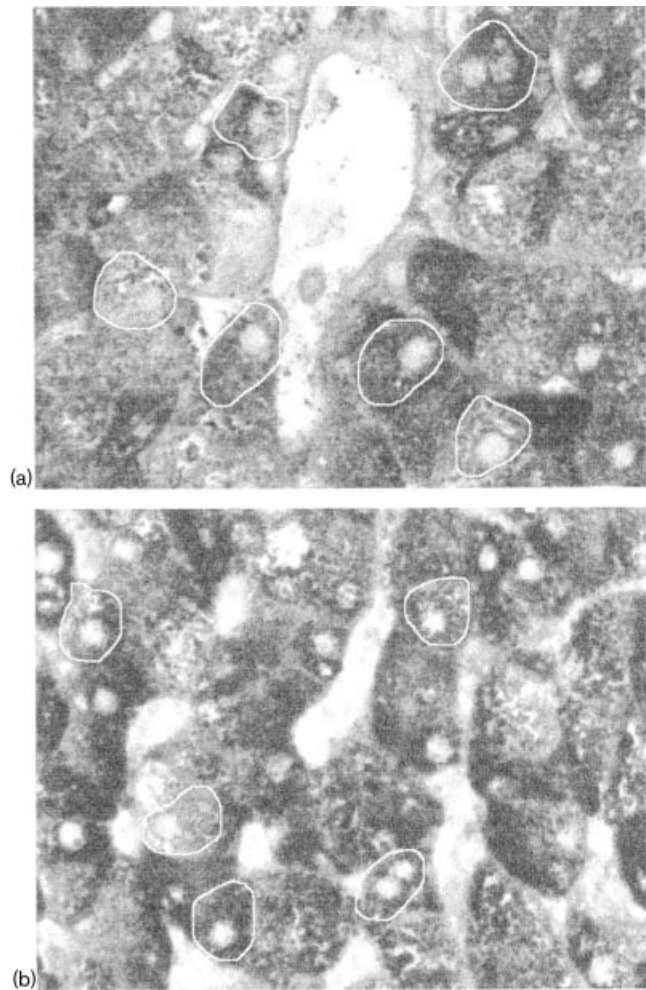
The study was performed on liver samples obtained by supravital punctate biopsy in three groups of men. The first group consisted of 17 males with diagnosed chronic viral hepatitis C at the stage of liver cirrhosis. The second group consisted of 15 males with liver cirrhosis of alcoholic aetiology; in these patients, viral aetiology of cirrhosis was ruled out by an immunochemical analysis of the biopsy material. The third group served as controls; it included 14 males whose livers were revealed by histological, immunochemical and biochemical methods to have no lesions. The mean age of the cirrhotic patients and the control group was 58 ± 6 and 52 ± 4 years, respectively. All the biopsies were performed at the same time (10–11 a.m.) on an empty stomach. The biopsy samples were fixed in 10% neutral formalin and embedded in paraffin. The sections were cut to a thickness of about 5 μm . The thickness of the sections was recorded using an MBIN-4 interference microscope (LOMO, St Petersburg, Russia).

Glycogen and its fractions were revealed histochemically using a modified PAS reaction [15]. Oxidation of cell glycogen was performed with 0.8% solution of KIO_4 in 0.3% water solution of HNO_3 at pH 2.0 and 20 °C for 90 min. The sections were then stained with Schiff reagent for 40 min (for determination of the labile glycogen fraction, LF) or 90 min (for TG), washed in water, treated with SO_2 -water, washed for 20 min in running water, treated with alcohol, and embedded in Canada balsam. The stable glycogen fraction (SF) was calculated as the difference between TG and LF.

Concentration of TG and its LF in individual hepatocytes of the portal and central liver lobule zones was determined using a Videotest image analyser (Ista-Videotest Company, Ltd, St Petersburg, Russia), which allows a combination of cytophotometric analysis of the amount of substance in the cell with determination of its precise localization in the tissue [16]. As a parameter proportional to glycogen concentration, the mean cell optical density D_c was used. For this purpose, in the interactive regimen, a light-pen was used to mark hepatocytes on the monitor of the section image. The hepatocytes were located around the portal and central veins within the radius of five cells (Fig. 1). The integral optical density S_i measured in the carted preparation is the sum of local densities of all elements of the object image, while the D_c is equal to S_i/N , where N is the number of image elements belonging to the given object.

The measurements were carried out in monochromatic

Fig. 1



Sections of the portal (a) and central (b) zones of the human cirrhotic liver lobule on the screen of the image analyser monitor. Contours of the cells in which the glycogen content was measured in this section is stained with PAS reaction.

light (interference light filter, $\lambda_{\text{max}} = 545 \text{ nm}$), using the objective 40×0.65 . In each patient, the glycogen content was measured in 100 hepatocytes of the portal and central liver lobule zones.

The statistical significance of the differences of the mean values of the glycogen content in cells of the portal and central zones and of the ratio of the glycogen concentrations in the portal zone to the central zone (P/C) values were calculated using the t -criterion. The standard errors of the P/C values were found from the formula of the error determination in quotients.

The preparations were photographed using an Amplival microscope (Carl Zeiss, Jena, Germany) with objective lens 20×0.40 and eye piece $4 \times$.

Results

Structure of the liver parenchyma

Examination of the morphological picture of human liver sections after performance of PAS reaction has shown that the liver parenchyma is normally characterized by a radial arrangement of hepatocytes around central veins, and the presence of a clear lobular structure (Fig. 2a). In cirrhosis, the lobular liver structure is absent. However, in patients with viral or alcoholic cirrhosis it is possible to find rare parenchyma sites in which the lobules are discernible reliably (Figs 2b and 2c).

Glycogen content

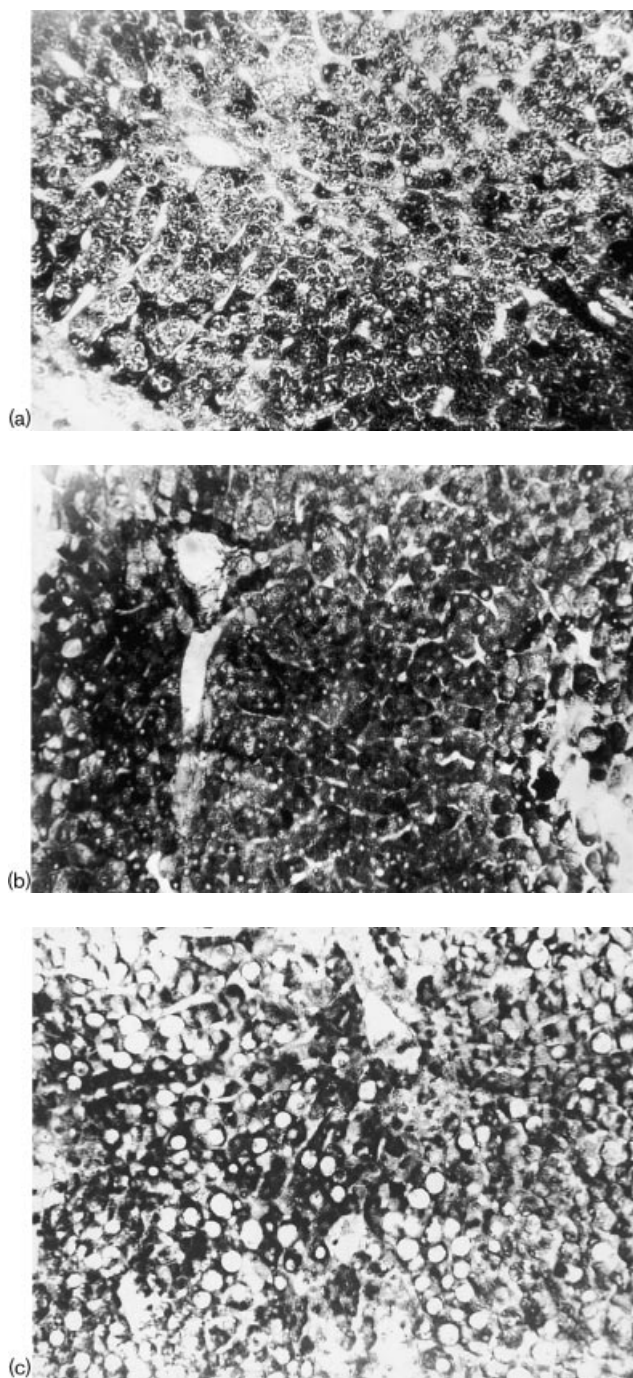
Results of measurements of the TG concentration in hepatocytes of different liver lobule zones in normal liver and in the patients with cirrhosis of different aetiologies are presented in Table 1. As seen from this table, the TG concentrations in both lobule zones in the cirrhotic patients are higher than in normal liver. TG concentrations are increased 23% and 45% in the portal and central zones, respectively, in the patients with viral cirrhosis. In alcoholic cirrhosis, the TG concentration in hepatocytes of the lobule portal zone is increased by 23%, whereas in the central zone cells, 78%.

The fractional glycogen composition both in the central and portal liver lobule zones in viral cirrhosis did not differ significantly from the norm (Table 1). The percentage of LF in hepatocytes amounted to about 79% in viral cirrhosis, compared with 83% in normal liver. In alcoholic cirrhosis, the LF percentage in the portal zone was reduced markedly to 66%, while in the central zone it exceeded the normal value slightly but significantly (88%).

Table 2 presents data on the ratio of the TG and LF concentrations in the portal zone hepatocytes to the TG and LF concentrations in the central zone cells. This ratio (P/C) for the TG in normal liver is seen to amount to 1.264, which indicates that more TG is present in the portal zone of the liver lobule. The predominance of the portal-zone TG is preserved in viral liver cirrhosis (Tables 1 and 2). However, in alcoholic cirrhosis the P/C ratio is 1.030, i.e. 1.2 times lower than in normal liver. Meanwhile, in alcoholic liver cirrhosis, the P/C ratio was as low as 0.815 (Table 2), i.e. the TG concentration in the central zone hepatocytes in this pathology is higher than in the portal zone cells.

As seen from Table 2, in viral liver cirrhosis, in spite of the P/C ratio reduction for the TG, the P/C ratio for LF concentrations does not differ significantly from the normal P/C value. Meanwhile, in alcoholic cirrhosis the intensive TG accumulation in central zone hepatocytes

Fig. 2



Sections of the human liver. (a) Healthy human liver; (b) liver of a patient with cirrhosis of viral aetiology; (c) liver of a patient with cirrhosis of alcohol aetiology. The sections are stained with PAS reaction. Objective lens 0.20 \times , eye-piece lens 4 \times .

is accompanied by an essential change of the glycogen structure in the portal zone cells: in the latter, the percentage of LF decreases, while that of SF increases correspondingly (Table 1). As a result, the P/C ratio for LF in alcoholic cirrhosis is reduced to a greater extent

Table 1 The mean content (arbitrary units) of total glycogen (TG), its labile fraction (LF) and its stable fraction (SF) in different zones of the liver lobule of healthy subjects and patients with liver cirrhosis of viral and alcoholic aetiology

	Portal zone			Central zone		
	TG	LF	SF	TG	LF	SF
Patients without cirrhosis, <i>n</i> = 14	0.232 ± 0.090	0.193 ± 0.007	0.025 ± 0.009	0.165 ± 0.012	0.138 ± 0.008	0.019 ± 0.012
Patients with cirrhosis of viral aetiology, <i>n</i> = 17	0.286 ± 0.011	0.227 ± 0.011	0.054 ± 0.009	0.240 ± 0.007	0.189 ± 0.010	0.049 ± 0.008
Patients with cirrhosis of alcoholic aetiology, <i>n</i> = 15	0.287 ± 0.008	0.190 ± 0.017	0.092 ± 0.011	0.324 ± 0.014	0.284 ± 0.022	0.051 ± 0.010

Table 2 Ratio of the contents of total glycogen (TG), its labile fraction (LF) and its stable fraction (SF) in hepatocytes of the liver portal zone to their contents in hepatocytes of the central zone

	Normal			Cirrhosis of viral aetiology			Cirrhosis of alcoholic aetiology		
	TG	LF	SF	TG	LF	SF	TG	LF	SF
Mean	1.264 ± 0.021	1.322 ± 0.015	1.299 ± 0.031	1.030 ± 0.009	1.264 ± 0.021	1.104 ± 0.025	0.815 ± 0.016	0.652 ± 0.017	1.716 ± 0.061

than the P/C for TG, and becomes as low as 0.652 (Table 2).

Discussion

We have observed earlier a several-fold accumulation of glycogen in human and animal hepatocytes in chronic hepatitis and liver cirrhosis [6,8–10]. This hepatocytic glycogenesis was found to depend markedly on the severity of the liver pathology, but not on the aetiology of the disease. Chronic liver diseases in humans have been established to lead not only to pronounced glycogen deposits in hepatocytes, but also to characteristic changes of the glycogen distribution in the liver lobule [11,13]. In both normal liver and chronic viral hepatitis B, the ratio of the glycogen levels in the portal and central lobule zones (the P/C ratio) was higher than 1.0, amounting on average to 1.128 and 1.061, respectively. Unlike chronic viral hepatitis, chronic alcoholic hepatitis was characterized by a higher hepatocytic glycogen concentration in the central than in the portal lobule zone, so the P/C became lower than 1.0 (0.930).

In the present work, concentration of glycogen in hepatocytes of patients with liver cirrhosis has been found to be much higher than in normal liver. In these patients, there were also changes in the glycogen distribution inside the liver lobule. In viral cirrhosis, the P/C value, although reduced, remained greater than 1.0, whereas in alcoholic cirrhosis, due to the glycogen concentration in the central zone exceeding that in the portal zone, the P/C ratio became less than 1.0 (Table 2).

Thus, progression of chronic hepatitis to liver cirrhosis increases reconstruction of glycogen metabolism in both zones of the liver lobule. This reconstruction is

manifested as a reduction of the P/C ratio, more pronounced in alcoholic cirrhosis.

Our previous data indicate that chronic pathologies in animal and human liver lead not only to a progressive accumulation of glycogen in hepatocytes, but also to changes in structure. Thus, in chronic hepatitis in patients and in CCl₄-produced liver cirrhosis in rats, the percentage of the glycogen LF was decreased significantly compared with the norm [6,17]. Meanwhile, we failed to find in the available literature any data on the fractional composition of glycogen in different lobule zones in chronic liver diseases. Our determinations (Table 2) indicate that in viral cirrhosis, a rise of glycogen concentration in hepatocytes is not accompanied by changes of the glycogen fractional composition, whereas in alcoholic cirrhosis, the glycogen accumulation is accompanied by a significant change of its composition in hepatocytes of both lobule zones.

At present, information on the mechanisms of metabolic disturbances in different liver lobule zones in the course of development of cirrhosis is scarce. It must be kept in mind that, in the normal lobule of human and animal liver, the gradient of glycogen and activities of enzymes responsible for its metabolism are associated closely with oxygen partial pressure, the value of the glucagon/insulin ratio, concentrations of substrates, and other factors [2,4,18,19]. Therefore, it seems reasonable to assume essential changes, as compared with the norm, of concentrations of these substances in lobules of the cirrhotically altered liver. Indeed, in the cirrhotic liver such changes were revealed in activities of a number of oxidative enzymes as well as in metabolism of amino acids and glucose [18,20–22].

At present, increasing evidence is accumulated in favour of the suggestion that the cirrhotic liver parenchyma is not a chaotic cell agglomeration but is a tissue with a definite organization. On the one hand, there is a point of view that even under conditions of constant cell death and parenchyma regeneration, proliferation of connective tissue, and circulation disturbances, the cirrhotic tissue is capable of maintaining functional organization of parenchyma and of providing its metabolic zonation. The anatomical nodule in cirrhosis is believed to replace the primary structure of the liver lobule to become a certain functional unit of the cirrhotic parenchyma [23]. In such a model, depending on the aetiology of cirrhosis, afferent vessels can be located in the centre of the cirrhotic nodule, thereby this zone can be considered an analogue of the periportal zone, whereas efferent vessels can be present at the nodule periphery (the pericentral zone), which takes place, for instance, in the case of toxic CCl₄-produced cirrhosis, or vice versa (as in the case of biliary cirrhosis). The location of afferent and efferent vessels in the cirrhotic nodules is thought to depend on the location of the initial liver damage [23,24].

On the other hand, some authors believe that in cirrhosis, in the process of liver lesion, not every lobule is necessarily damaged [14]. Parts of the lobules in the cirrhotically altered liver could preserve the initial structure and metabolic zonation. However, even in this case, as has been shown in this study, depending on the aetiology of the cirrhosis, essential changes occur in the gradient of glycogen, its fractional composition, and probably the organization of its metabolism.

Thus, our study has revealed significant changes in the content and localization of the total glycogen and its fractions in different zones of the liver lobule. We have established that whereas the total glycogen content in hepatocytes is an important characteristic of the degree of liver lesion, the ratio of its content in the portal and central liver lobule zones characterizes the aetiology of liver cirrhosis, which is of particular importance for diagnosis of this pathology.

References

- Sasse D. Dynamics of liver glycogen: the topochemistry of glycogen synthesis, glycogen content and glycogenolysis under the experimental conditions of glycogen accumulation and depletion. *Histochemistry* 1975; **45**:237–254.
- Jungermann K. Functional heterogeneity of periportal and perivenous hepatocytes. *Enzyme* 1986; **35**:161–180.
- Jungermann K, Katz N. *Metabolism of Carbohydrates. Regulation of Hepatic Metabolism*. New York: Plenum Press; 1986.
- Jungermann K. Role of intralobular compartmentation in hepatic metabolism. *Diabete Metab* 1992; **18**:81–86.
- Kruszynska YG, McIntyre N. Relationship between insulin sensitivity, insulin secretion and glucose tolerance in cirrhosis. *Hepatology* 1991; **14**:103–111.
- Kudryavtseva MV. Glycogenesis of liver cells in chronic hepatitis and its diagnostic significance. *Adv Hepatol* 1987; **13**:201–211.
- Kudryavtseva MV, Skorina AD, Kudryavtsev BN, Deineka ZG. Cytofluorimetric study of glycogen fractions in liver cells of patients with chronic viral and alcoholic hepatitis. *Tsitologiya* 1988; **30**:705–706.
- Kudryavtseva MV, Emelyanov AV, Sakuta GA, Skorina AD, Sleptsova AD, Kudryavtsev BN. Cytofluorimetric study of the content of glycogen and its fractions in hepatocytes of patients with liver cirrhosis of different etiology. *Tsitologiya* 1992; **34**:100–107.
- Kudryavtseva MV, Emelyanov AV, Sakuta GA, Bezborodkina NN, Kudryavtsev BN. Glycogen-forming function of hepatocytes in the rat regenerating cirrhotic liver after a partial hepatectomy. *Tissue Cell* 1998; **30**:200–206.
- Kudryavtseva MV, Bezborodkina NN, Kudryavtsev BN. Restoration of the glycogen-forming function of hepatocytes in rats with liver cirrhosis is facilitated by a high-carbohydrate diet. *Br J Nutr* 1999; **81**:473–480.
- Kudryavtseva MV, Sakuta GA, Skorina AD, Stein GI, Emelyanov AV, Kudryavtsev BN. Quantitative estimation of the glycogen content in hepatocytes of different zones of the human liver in norm and in chronic hepatitis of different etiology. *Tsitologiya* 1995; **37**:470–480.
- Kudryavtseva MV, Emelyanov AV, Sakuta GA, Kudryavtsev BN. Glycogen-forming function of hepatocytes under conditions of regeneration of rat cirrhotic liver after a partial hepatectomy. *Tsitologiya* 1996; **38**:934–948.
- Kudryavtseva MV, Sakuta GA, Skorina AD, Stein GI, Emelyanov AV, Kudryavtsev BN. Quantitative analysis of glycogen content in hepatocytes of portal and central lobule zones of normal human liver and in patients with chronic hepatitis of different etiology. *Tissue Cell* 1996; **28**:279–285.
- Racine-Samson L, Scoazes JY, D'Errico A, Fiorentino M, Christa L, Moreau A, et al. The metabolic organization of the adult human liver: a comparative study of normal, fibrotic, and cirrhotic liver tissue. *Hepatology* 1996; **24**:104–113.
- Kudryavtseva MV, Kudryavtsev BN, Rozanov YuM. On two glycogen fractions in rat liver cells (cytofluorimetric study). *Tsitologiya* 1974; **16**:851–858.
- Stein GI, Panteleev VG, Povarkova AV, Kudryavtsev BN. Possibilities of the image analyser "Videotest" for performance of microphotometric studies in cytology. *Tsitologiya* 1998; **40**:913–916.
- Kudryavtseva MV, Sakuta GA, Stein GI, Kudryavtsev BN. Dynamics of the glycogen synthesis in different zones of the rat liver lobules. *Tsitologiya* 1990; **32**:1010–1018.
- Thurman RG, Forchand BJ, Apel ED, Lemasters JJ. Role of oxygen in hepatic carbohydrate metabolism and ethanol toxicity. In: *Biomedical and Social Aspects of Alcohol and Alcoholism*. Amsterdam: Elsevier; 1988. pp. 171–176.
- Ikezawa Y, Yamatani K, Ogawa A, Ohnuma H, Igarashi M, Daimon M, et al. Effects of glucagon on glycogenolysis and gluconeogenesis are region-specific in periportal and perivenous hepatocytes. *J Lab Clin Med* 1998; **132**:547–555.
- Jonges GN, Van Noorden CJ, Lamers WH. *In situ* kinetic parameters of glucose-6-phosphatase in the rat liver lobules. *J Biol Chem* 1992; **267**:4878–4881.
- Bugianesi E, Kalhan S, Burkett E, Marchesini G, McCullough A. Quantification of gluconeogenesis in cirrhosis: response to glucagon. *Gastroenterology* 1998; **115**:1530–1540.
- Petersen KF, Krssak M, Navarro V, Chandramouli V, Hundal R, Schumann WC, et al. Contributions of net hepatic glycogenolysis and gluconeogenesis to glucose production in cirrhosis. *Am J Physiol* 1999; **276**:E529–E535.
- Sokal EM, Collette E, Buts JP. Continuous increase of alcohol dehydrogenase activity along the liver plate in normal and cirrhotic human liver. *Hepatology* 1993; **17**:202–205.
- Sokal EM, Trivedi P, Portmann B, Mowat AP. Adaptive changes of metabolic zonation during the development of cirrhosis in growing rats. *Gastroenterology* 1990; **99**:785–792.